

## Pediatric Major Trauma: An Approach to Evaluation and Management

Jahn T. Avarello, MD, FAAP<sup>a,\*</sup>,  
Richard M. Cantor, MD, FAAP, FACEP<sup>a,b</sup>

<sup>a</sup>*Department of Emergency Medicine, SUNY Upstate Medical University,  
750 East Adams Street, Syracuse, NY 13210, USA*

<sup>b</sup>*Central New York Poison Center, 750 East Adams Street, Syracuse, NY 13210, USA*

More than 45% of all deaths in children from 1 to 14 years are the result of trauma. Over 5000 traumatic deaths per year occur within this age group; 80% of these mortalities were unintentional and 47% directly related to motor vehicle collisions (MVCs). Injury accounts for approximately 5% of infant deaths as well [1,2]. Nationwide estimates of mortality for children hospitalized after injury are uniformly low; however, most fatalities occur in the field before arrival at a health care facility. This contributes to an underestimation of the magnitude of overall mortality figures.

The most common single organ system injury associated with death in injured children is head trauma [3,4]. Rates of 80% have been reported in patients with combined thoracoabdominal injuries [1,5]. Because multiple injury is common in children, the emergency physician (EP) must evaluate all organ systems in any injured child, regardless of the actual mechanism of injury.

Within the subset of MVC, death rates begin to climb steeply in children 13 years of age and beyond. MVC mortality statistics demonstrate that the youngest occupant in the vehicle is the most vulnerable to injury. Within the school-age group of 5 to 9 years old, pedestrian injuries and bicycle crashes predominate. Submersion injury accounts for 10% to 15% of injury, burns 5% to 10%, and falls from heights approximately 2% [5–7]. Nationwide, the number of children who are victims of violent acts has decreased by 39% from 1994 to 2004. Even with this significant decline, 13% of all traumatic deaths in the age group of children 1 to 14 years old were a result of

---

\* Corresponding author.

*E-mail address:* [avarellj@upstate.edu](mailto:avarellj@upstate.edu) (J.T. Avarello).

homicide in 2004 [2,8]. The leading causes of traumatic death in the United States are listed in Table 1.

### Principles of disease

There are major anatomic, physiologic, and psychological differences in the pediatric and adult patients that play a significant role in the evaluation and management of the pediatric trauma patient. A summary of overall anatomic differences and their implications in the pediatric trauma patient are listed in Box 1. Anatomic differences in the pediatric and adult airway and their implication in the pediatric trauma patient are listed in Table 2.

Compared with adults, in children, any given force is more widely distributed though the body, making multiple injuries significantly more likely to occur. The proportionately large surface area of an infant or child relative to weight predisposes them to greater amounts of heat loss as a result of evaporation. Maintenance requirements for free water, trace metals, and minerals are therefore magnified to a greater degree. All these factors contribute to a significantly higher energy and caloric requirement for the injured child when compared with an injured adult. Physiologically, children respond to injury quite differently than adults, depending on the age and maturation of the child and the severity of the injury. Unlike adults, children have a great capacity to maintain blood pressure despite significant acute blood losses (25% to 30%). Subtle changes in heart rate, blood pressure, and extremity perfusion may indicate impending cardiorespiratory failure and should not be overlooked. Finally, children may not cope well outside of their usual environment. They are often disproportionately irritable relative to their degree of injury, making assessment all the more difficult. Recent evidence suggests that 25% of children involved in road traffic accidents will show signs of posttraumatic stress disorder after discharge [9]. They need to be approached in a calming and sometimes unconventional manner so as to lessen their anxiety.

Table 1  
Leading causes of traumatic deaths in children 1 to 14 years of age in the United States—2004

Etiology	No.	%
Motor Vehicle Accidents	2,026	38.2
Homicide	706	13.3
Drowning <sup>a</sup>	699	13.2
Fire/Burn <sup>a</sup>	484	9.1
Suicide	285	5.4
Suffocation <sup>a</sup>	238	4.5
Other	860	16.3

<sup>a</sup> Unintentional.

**Box 1. Anatomic difference in adults and children—implications for pediatric trauma management**

- The child's body size allows for a greater distribution of traumatic injuries, therefore multiple trauma is common.
- The child's greater relative body surface area also causes greater heat loss.
- The child's internal organs are more susceptible to injury based on more anterior placement of liver and spleen and less protective musculature and subcutaneous tissue mass.
- The child's kidney is less well protected and more mobile, making it very susceptible to deceleration injury.
- The child's growth plates are not yet closed, leading to Salter-type fractures with possible limb-length abnormalities with healing.
- The child's head-to-body ratio is greater, the brain less myelinated, and cranial bones thinner, resulting in more serious head injury.

---

*From Marx JA, Holberger RS. Rosen's emergency medicine: concepts and clinical practice. 5th edition. Mosby; 2002. p. 267–81; with permission.*

**Clinical features***Initial assessment priorities/primary survey*

The highest priority in the approach to the injured child is ruling out the presence of life- or limb-threatening injury. Treatment of these injuries must occur before proceeding with the rest of the physical examination. This initial assessment (the primary survey) and necessary initial resuscitation efforts must occur simultaneously. In general, they should be addressed within the first 5 to 10 minutes of evaluation.

Any infant or child with a potentially serious or unstable injury requires continual reassessment. Vital signs should be repeated every 5 minutes during the primary survey and every 15 minutes thereafter until the patient is considered stable.

The International Liaison Committee on Resuscitation (ILCOR) pediatric task force is a multinational team of expert reviewers that was assigned to review resuscitation science and develop an evidence-based consensus to guide resuscitation practices. In January of 2005, the ILCOR presented the evidence at the International Consensus Conference on Cardiopulmonary Resuscitation and Emergency Cardiovascular Care Science With Treatment Recommendations, hosted by the American Heart Association (AHA). By the end of the conference some major changes to the Pediatric Advanced Life Support (PALS) guidelines were established and simultaneously

Table 2  
Anatomic differences in the pediatric airway—implications in pediatric trauma management

Differences	Implications
Relatively larger tongue, which can obstruct the airway	Most common cause of airway obstruction in children May necessitate better head positioning or use of airway adjunct (oropharyngeal [OP] or nasopharyngeal [NP] airway)
Larger mass of adenoidal tissues may make nasotracheal intubation more difficult	NP airways may also be more difficult to pass in infants <1 year of age
Epiglottis is floppy and more Ω-shaped	Necessitates use of a straight blade in young children
Larynx more cephalad and anterior	More difficult to visualize the cords; may need to get lower than the patient and look up at 45-degree angle or greater while intubating
Cricoid ring is the narrowest portion of the airway	Provides natural seal and allows for use of uncuffed tubes in children up to size 6 mm or about 8 years of age
Narrow tracheal diameter and distance between the rings, making tracheostomy more difficult	Needle cricothyrotomy for the difficult airway versus a surgical cricothyrotomy for the same reason
Shorter tracheal length (4 to 5 cm in newborn and 7 to 8 cm in 18-month-old)	Leading to intubation of right mainstem or dislodgement of the endotracheal tube
Large airways are more narrow	Leads to greater airway resistance ( $R = 1/\text{radius}^4$ )

From Marx JA, Holberger RS. Rosen's emergency medicine: concepts and clinical practice. 5th edition. Mosby; 2002. p. 267–81; with permission.

published in *Circulation* and *Resuscitation* in November 2005. A summary of these changes can be found in the winter 2005 to 2006 issue of AHA-published *CURRENTS in Emergency Cardiovascular Care*.

### Primary survey

**Airway.** Indications for endotracheal intubation of the pediatric trauma patient include (1) any inability to ventilate by bag-valve-mask (BVM) methods or the need for prolonged control of the airway; (2) Glasgow Coma Scale (GCS) score of  $\leq 8$  to secure the airway and provide controlled hyperventilation as indicated; (3) respiratory failure from hypoxemia (eg, flail chest, pulmonary contusions) or hypoventilation (injury to airway structures); (4) any trauma patient in decompensated shock resistant to initial fluid administration; and (5) the loss of protective laryngeal reflexes. With these indications in mind, it is also important to know that endotracheal intubation may not be the most effective means of ventilation in the prehospital setting. In 2000, Gausche and colleagues [10] published data in *JAMA* presenting good evidence that BVM is as effective and may be safer than endotracheal intubation in the prehospital setting. Patients

were randomized to receive either BVM or endotracheal intubation. Of the 830 pediatric patients enrolled, there was a 4% better survival rate and a 3% better neurologic outcome rate in the BVM group with even more significance in the subgroups of respiratory arrest and child maltreatment. The AHA included these findings in their PALS updates stating to “ventilate and oxygenate infants and children with a bag-mask device, especially if transport time is short” [10].

Intubation of the pediatric patient involves special considerations. Cuffed endotracheal tubes have recently been considered as safe as uncuffed tubes for infants beyond the newborn period and in children when in the hospital setting. The 2005 update by the AHA states “In certain circumstances (eg, poor lung compliance, high airway resistance, or a large glottic air leak) a cuffed tube may be preferable provided that attention is paid to endotracheal tube size, position, and cuff inflation pressure” [11]. On the contrary, in patients younger than 8 years who do not fit those circumstances, uncuffed tubes should be used, as the narrowest portion of the pediatric airway in this age group is at the level of the cricoid cartilage (Table 2). For children 1 to 10 years of age, the following formulas may be used for estimation of proper endotracheal tube size (ID, internal diameter):

- Uncuffed endotracheal tube size (mm ID) = (age in years + 16)/4
- Cuffed endotracheal tube size (mm ID) = (age in years + 12)/4

In general, the orotracheal approach is recommended. Problems associated with nasotracheal intubation include inherent difficulties in children, impairment of tube passage by the acute angle of the posterior pharynx, and the probability of causing or worsening bleeding within the oral cavity and causing increases in intracranial pressure (ICP) with insertion.

*Breathing/ventilation.* Assess for adequacy of chest rise. In a young child this will occur in the lower chest and upper abdomen. Also assess respiratory rate. Rates that are too fast or slow can indicate impending respiratory failure. Treatment is assisted ventilation. If ventilation is necessary, a BVM device is recommended initially. Be careful to provide only the volume necessary to cause the chest to rise, because excessive volume or rate of ventilation can increase the likelihood of gastric distention and further impair ventilation. Once an advanced airway is placed, ventilations should be given at a rate of 1 breath every 6 to 8 seconds (8 to 10 breaths per minute). Cricoid pressure may be useful to decrease the amount of air entering the esophagus during positive-pressure ventilation. With regard to assessment of ventilation, early monitoring with pulse oximetry is very useful; however, pulse oximetry will measure adequacy of oxygenation only. There are many limiting factors that compromise ventilatory function in the injured child, including depressed sensorium, occlusion of the airway itself, painful restriction of lung expansion, and direct pulmonary injury. Determination of adequate ventilation is possible only in

the face of airway patency and adequate air exchange. The diaphragm plays a special role in the maintenance of proper ventilatory status in children. It is easily fatigued in the young child and is often displaced by any process that promotes distention of the stomach. In this regard, it is advisable to consider early placement of a nasogastric tube to facilitate decompression of the stomach.

*Circulation and hemorrhage control.* Assessment of circulation in a child involves a combination of factors, namely the pulse, skin color, and capillary refill time. In a child, maintenance of systolic blood pressure does not ensure that the patient is not in shock, a direct effect of the ability of the pediatric vasculature to constrict and increase systemic vascular resistance in an attempt to maintain perfusion. Therefore skin signs such as cool distal extremities, decreases in peripheral versus central pulse quality, and delayed capillary refill time are signs of pediatric shock, even when blood pressure is maintained. The lowest acceptable blood pressures for age (5th percentile) are as follows [11]:

- 60 mm Hg in term neonates (0 to 28 days)
- 70 mm Hg in infants (1 month to 12 months)
- 70 mm Hg + (2 × age in years) in children 1 to 10 years of age
- 90 mm HG in children ≥ 10 years of age

In general, a palpable peripheral pulse correlates with a systolic blood pressure greater than 80 mm Hg and a palpable central pulse with a pressure greater than 50 to 60 mm Hg [12]. Normal capillary refill times are less than 2 seconds. Alteration in a child's response to the environment or interaction with caregivers may also indicate respiratory failure or shock. External hemorrhage should be sought for and controlled with direct pressure.

All pediatric patients involved in major trauma should be placed on a cardiac monitor, receive supplemental oxygen, and have constant reassessment of vital signs and oximetry. Vascular access is best obtained by accessing the upper extremity for the establishment of two large-bore intravenous (IV) lines. In the absence of available upper extremity peripheral sites, lower extremity sites could be used, and many clinicians favor the femoral vein as a safe site for insertion of a central line, by use of a guide wire technique. If cutdowns are necessary, the antecubital or saphenous sites will suffice. If access is needed emergently or if there is no success in the first 5 minutes of an urgent scenario, intraosseous access may be obtained at the proximal medial tibia 1 cm below and medial to the tibial tuberosity, the distal tibia 1 to 2 cm proximal to the medial malleolus, or the lower third of the femur at the midline 3 cm above the lateral condyle (Fig. 1) [13]. The intraosseous route serves as an appropriate venous access site; however, delivery rate of large amounts of crystalloid solutions is limited based on maximum flow rates of approximately 25 mL/min [14–16]. Intraosseous placement in a fractured extremity is contraindicated.

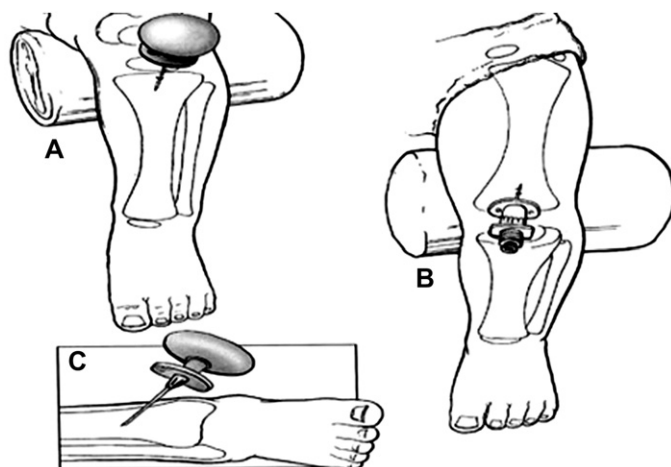


Fig. 1. (A–C) Preferred locations for intraosseous needle placement. (Reprinted from Fleisher GR, Ludwig S, Henretig FM. Textbook of pediatric emergency medicine. 5th edition. Philadelphia: Lippincott Williams and Wilkins; 2006. p. 1879; with permission.)

Most hypovolemic pediatric trauma patients respond to infusions of 20 mL/kg of isotonic crystalloid solutions. If 40 mL/kg has already been given and a third bolus is still required to reverse systemic signs of hypoperfusion, an infusion of packed blood cells at 10 mL/kg should be considered [17]. In patients who present in decompensated shock or cardiopulmonary failure, and occult bleeding is a potential cause for the shock, administer crystalloid and blood products simultaneously.

In contrast to the adult, cardiogenic shock is a rare event in the face of childhood injury [3,18]. However, any degree of chest trauma associated with the presence of shock must alert the clinician to the possibility of concomitant myocardial contusion or rupture. The classic presentation of neurogenic shock, involving hypotension without an increase in heart rate or compensatory vasoconstriction, should be considered in patients with head or neck injuries.

With regard to cardiopulmonary resuscitation (CPR) in the infant and child, the guidelines have been recently updated. The chest compression-ventilation ratio for one lay rescuer and one lone health care provider is now 30:2, and 15:2 for health care providers performing two-rescuer CPR. Although these recommendations come mostly from theoretical data and rational conjecture, the thought is that, besides less fatigue of the rescuer(s), more interruptions in chest compressions will prolong the duration of low coronary perfusion pressures reducing the likelihood of a return of spontaneous circulation. High-dose epinephrine has been removed from the recommendation with the exceptions being if it is administered by the endotracheal route or in exceptional circumstances such as  $\beta$ -blocker overdose.

*Disability assessment (thorough neurologic examination).* To assess patient disability, there is need for a rapid neurologic evaluation. The GCS (Boxes 2 and 3) and the AVPU System (Box 4) are used for a rapid neurological evaluation. It is important to rule out hypoglycemia in any patient with altered mental status. This is particularly important in younger children since their glycogen stores are easily depleted, predisposing them to hypoglycemia.

*Exposure.* The final component of the primary survey involves fully undressing the patient to assess for hidden injury. Maintenance of normothermia is of paramount importance in the toddler and infant during the exposure phase because metabolic needs are greatly increased by hypothermia.

*Family.* In the management of children, the family could be added to the primary survey. Rapidly informing the family of what has happened and the evaluation that is proceeding will help lessen the stress of the caregivers. Allowing family presence during resuscitations is acceptable and often preferred by families. Some caregivers will choose not to be present, but that choice should be given to them. If a caregiver is present, it is advisable to assign a staff member to be with them during the trauma resuscitation to explain the process [19].

## **Box 2. Glasgow Coma Scale**

### *Eye opening response (1–4 points)*

4. Spontaneous
3. To verbal stimuli
2. To painful stimuli
1. None

### *Verbal response (1–5 points)*

5. Oriented
4. Confused
3. Inappropriate words
2. Nonspecific sounds or incomprehensible
1. None

### *Motor response (1–6 points)*

6. Normal spontaneous movements
5. Localizes painful stimuli
4. Withdraws from painful stimuli
3. Abnormal flexion (decorticate rigidity)
2. Abnormal extension (decerebrate rigidity)
1. None



**Box 3. Modified GCS***Modified GCS for infants**Eye opening response (1–4 points)*

4. Spontaneous
3. To verbal stimuli
2. To painful stimuli
1. None

*Verbal response (1–5 points)*

5. Coos and/or babbles
4. Irritable and continuous crying
3. Cries to painful stimuli
2. Moans to painful stimuli
1. None

*Motor response (1–6 points)*

6. Spontaneous purposeful movements
5. Withdraws to touch
4. Withdraws to painful stimuli
3. Abnormal flexion (decorticate rigidity)
2. Abnormal extension (decerebrate rigidity)
1. None

*Secondary survey*

The secondary survey is designed to assess the patient and treat additional injury not found on the primary survey and also to obtain a more complete and detailed history. Features of the detailed history that need to be obtained can be remembered by the mnemonic *AMPLE* (Box 5). During the secondary survey the EP should attend to the tasks outlined in Box 6.

Specifics of the head examination include pupillary size and reactivity, funduscopic examination, and palpation of the skull itself. Assessment of the cervical spine must be done carefully, with the patient in full c-spine immobilization.

Assessment of the chest and internal structures involves inspection for wounds and flail segments, palpation for tenderness and crepitance, and

**Box 4. The AVPU system**

**A** = **A**lert

**V** = Responds to **V**erbal stimuli

**P** = Responds to **P**ainful stimuli

**U** = **U**nresponsive

**Box 5. The AMPLE history**

- A, Allergies**
- M, Medications**
- P, Past medical history**
- L, Last meal**
- E, Environments and events**

auscultation for asymmetry or poorly transmitted breath sounds or cardiac impulses.

Examination of the pediatric abdomen is most reliable when performed on a cooperative patient and should be considered an insensitive screening process for the presence of an injury when the patient has an associated head injury or a GCS  $\leq$  13 [20].

A rectal examination provides information concerning sphincter tone, prostatic position, and the presence of blood in the stool. Although urethral injury is rare in children, all trauma patients should be assessed for a perineal or lower abdominal hematoma and blood from the urethral meatus. Examination of the extremities is directed toward the evaluation of any deformities, penetrations, and interruptions of perfusion. Most fracture sites may be stabilized with splinting until surgical intervention can be performed. Early orthopedic consultation is advisable.

As mentioned previously, the pediatric patient is at great risk for the development of hypothermia. This is based on the large amount of surface area relative to body weight. Careful attention to core temperatures in these vulnerable patients is required, with early intervention as needed, with supplemental external warming techniques.

An overview of recommended interventions for the multiply traumatized child is contained in [Tables 3–8](#).

**Box 6. Tasks to be completed after the secondary survey**

- Complete head-to-toe examination
- Appropriate tetanus immunization
- Antibiotics as indicated
- Continued monitoring of vital signs
- Ensure urine output of 1 mL/kg/hr

---

*From Marx JA, Holberger RS. Rosen's emergency medicine: concepts and clinical practice. 5th edition. Mosby; 2002. p. 267–81; with permission.*

Table 3

Airway: assessment and treatment

Assessment priorities	Interventions
Airway patency	Jaw thrust, suction, airway adjuncts
Level of consciousness	Cervical spine immobilization
Maxillofacial injury	Apply 100% O <sub>2</sub> by mask
Stridor or cyanosis	Intubate for: Glasgow Coma Scale $\leq$ 8 or absent gag reflex or Po <sub>2</sub> < 50 or Pco <sub>2</sub> > 50 Needle cricothyrotomy if intubation impossible

### Laboratory

Blood sampling for the pediatric trauma patient is no different from that of the adult trauma patient; however, use of smaller blood collection tubes and microtechnique by laboratory staff may be necessary in infants and small children. All older children and adolescent trauma patients should be assessed for the possible use of drugs or alcohol as contributing factors to the traumatic event. In patients with hypovolemic shock, the hemoglobin alone is not sensitive because equilibration may not have occurred upon presentation to the emergency department (ED) [21,22].

### Radiology

The most important “traditional” radiographs to obtain on a moderately to severely injured child are of the chest and pelvis to assess for sites of blood loss or potential causes of shock. In stable, alert children without

Table 4

Breathing: assessment and treatment

Assessment priorities	Interventions
Respiratory rate	Oxygen 100% by nonbreather mask or intubate if in respiratory failure; fast rates may indicate shock (fluid resuscitation) or pain (parenteral analgesics)
Chest wall movements	For pneumo- or hemothorax: place chest tube Transfer to operating room if initial drainage >20 mL/kg or output >2 mL/kg/hr
Percussion note	Open pneumothorax: seal with occlusive dressing (vaseline gauze) followed by tube thoracostomy
Paradoxical breathing	Contusion/flail chest: intubate if tachypneic or Po <sub>2</sub> < 50 mm or Pco <sub>2</sub> > 50 mm Hg
Tracheal deviation	Tension pneumothorax: needle decompression at second intercostal space, midclavicular line, followed by placement of chest tube
Flail segments	Oxygen by nonbreather mask or intubate if in respiratory failure
Open wounds	Compress bleeding sites and cover as indicated

From Marx JA, Holberger RS. Rosen's emergency medicine: concepts and clinical practice. 5th edition. Mosby; 2002. p. 267–81; with permission.

Table 5  
Circulation: assessment and treatment

Assessment priorities	Interventions
Open wounds	Compress bleeding sites and cover as indicated
Capillary refill	Oximeter and cardiac monitor, oxygen and fluid resuscitation 20 mL/kg
Heart rate	Monitor vital signs every 5 minutes
Peripheral pulses	Two large-bore intravenous sites
Sensorium	Bolus with 20 mL/kg lactated Ringer's or normal saline solution (warm all intravenous fluids)
Pulse pressure	Repeat fluid bolus 2 times if necessary
Skin condition/perfusion	Packed red blood cells, 10–20 mL/kg for decompensated shock secondary to blood loss

distracting injuries, the pelvic film may be eliminated. The radiographs of the cervical spine may be delayed until after further diagnostic studies are obtained depending on the clinical presentation of the patient.

The diagnostic test of choice to assess intra-abdominal injury in stable trauma patients is rapid abdominal CT scanning [23]. The role of diagnostic peritoneal lavage (DPL) and Focused Abdominal Sonography for Trauma (FAST) is somewhat more limited although the FAST exam is gaining more acceptance [24,25]. As with all of these tests, the finding of intraperitoneal hemorrhage alone is not an indication for surgery in the pediatric patient (Box 7).

Other radiographs will be obtained based on the physical examination. For patients sustaining minor trauma, radiographs may not be needed. Finally, children younger than 2 years of age with injuries consistent with child abuse will need a skeletal survey including skull, chest, abdomen, and long-bone radiographs.

Table 6  
Disability: assessment and treatment

Assessment priorities	Interventions
Level of consciousness	Maintain blood pressure and oxygenation and ventilation
AVPU system or GCS	If head injury with GCS $\leq$ 8: RSI and intubate; head CT, neurosurgical consult
Pupil size and reactivity	If normotensive, consider mannitol 0.25–1 g/kg Hyperventilate Pco <sub>2</sub> to 30–35 mm Hg with signs of herniation
Extremity movement and tone	Stabilize spinal column If blunt cord trauma: methylprednisolone (See Table 9 for dosing recommendations)
Posturing	Hyperventilate Pco <sub>2</sub> to 30–35 mm Hg
Reflexes	Assess for signs of respiratory failure

*Abbreviation:* RSI, rapid sequence intubation.

Table 7  
Exposure: assessment and treatment

Assessment priorities	Interventions
Undress	Trauma examination including rectal examination
Look under collar and splints	Keep patient warm:
Log roll and examine back	<ul style="list-style-type: none"> <li>• Remove wet clothes</li> <li>• Place under heater</li> <li>• External warming devices</li> <li>• Warm blanket</li> <li>• Warm fluids</li> </ul>

### Specific disorders/injuries

#### *Head injury*

##### *Perspective*

Head trauma is the leading cause of death among injured children and is responsible for 80% of all trauma deaths [3]. Each year, 29,000 children younger than 19 years old suffer permanent disability from traumatic brain injury. In children younger than 14 years old, there are 475,000 hospital visits, 37,000 hospitalizations, and nearly 3000 deaths each year related to traumatic brain injury [4,26].

Falls account for 39% of pediatric head injuries, and MVCs are responsible for 11% [4,27,28]. In addition, pedestrian injuries account for 17% and falls from bicycles 10%. On an age-related basis, infants and toddlers are more prone to falls from their own height, school-age children are involved in sports injuries and MVCs, and all ages are subject to the sequelae of abuse [26].

##### *Clinical features*

In most cases it is important to establish whether there was loss of consciousness at the time of the injury event. With playground trauma, the history may be vague and the interpretation of any change in consciousness of the child may be regarded as an actual loss of consciousness. The behavior of the child after the event should include questions related to the presence or absence of irritability, lethargy, abnormal gait, or alterations in behavior. Most importantly, establishment of a timeline from the point of insult is helpful in determining whether there have been changes in the mental status of the patient. A caretaker present to establish the child's baseline behavior, mental status, and neurologic function is very useful.

The prognostic significance of vomiting after pediatric head trauma is uncertain [26,29]. There is no adequate study defining an acceptable time frame in which vomiting after head injury is benign in nature. The development of seizures after head trauma, in contrast to vomiting, has been well studied [30]. A brief seizure that occurs immediately after the insult (with rapid return of normal level of consciousness) is commonly called "an impact seizure" and is usually unassociated with intracranial parenchymal injury

Table 8  
Emergent management of increased intracranial pressure

Therapy	Dose	Mechanism of action
Head evaluation (30 degrees)		Lowers intracranial venous pressure
Head in midline		Prevents jugular vein compression
Hyperventilation	Reduces $Paco_2$ to 30–35 mm Hg	Promptly decreases cerebral blood volume and thus intracranial pressure Caution: too much ventilation can ↓ cerebral blood flow
Lidocaine	1–2 mg/kg IV	↓ airway reflex's that may ↑ intracranial pressure
Mannitol	0.25–1 g/kg IV	↓ blood viscosity → improved cerebral blood flow Contraindicated in hemodynamically unstable patients
Thiopental	3–5 mg/kg IV	Decreases cerebral metabolism reducing cerebral ischemic risk Caution with hypotensive patients
Etomidate	0.3 mg/kg IV	Decreases cerebral metabolism reducing cerebral ischemic risk
Emergent burr hole: Only in the rapidly deteriorating patient when all medical interventions have failed, a neurosurgeon is unavailable, and the patient will not likely survive transport		Temporary decompression to ameliorate herniation
Hypothermia (27°C–31°C)		Thought to decrease cerebral blood flow and metabolic rate; can cause cardiac dysrhythmias

*From Marx JA, Holberger RS. Rosen's emergency medicine: concepts and clinical practice. 5th edition. Mosby; 2002. p. 267–81; with permission.*

and in no way mandates the institution of anticonvulsant therapy. Seizures that occur later (longer than 20 minutes after the insult) portend the greater possibility of both internal injury and the development of seizures at a later date. Patients who experience seizures later in the course of the posttraumatic event are best evaluated by the neurosurgical service. As in all instances of trauma, a careful history related to the possibility of substance abuse must be obtained.

Table 9  
Corticosteroid treatment recommendations in acute spinal trauma

Indications	Acute spinal cord injury presenting within 8 hours of injury
Contraindications	(1) Patient presents >8 hrs postinjury (2) Gun shot injury (3) Pregnancy (4) Involvement of nerve root/cauda equina only (5) Other life threatening illness (6) Receiving maintenance steroids for other reasons (7) <13 years of age (relative contraindication)
Treatment	Methylprednisolone 30 mg/kg IV over 15 minutes then a 45-minute pause, then (1) 5.4 mg/kg/hr IV over 23 hrs if <3 hrs since injury OR (2) 5.4 mg/kg/hr IV over 47 hrs if 3–8 hrs since injury

*Data from Refs. [17,65,81].*

There are several methods for evaluating head-injured patients. These include AVPU and the GCS. The GCS has been modified for pediatric patients as illustrated in [Box 3](#).

The GCS more reliably predicts outcome of traumatic brain injury in children than in adults. In a study involving 80 children with traumatic brain injuries admitted to an intensive care unit (ICU), initial GCS scores were compared with eventual outcome. Both ICU lengths of stay and time to cognition relative to GCS scores indicated that scores greater than or equal to 6 were associated with favorable outcomes and neurologic status. While the numbers in this study are small, the important message is that no matter

#### **Box 7. Potential uses for the FAST examination**

- Rapidly identify the source of hypotension in the hemodynamically unstable patient
- Assist in decision making in the child with head and abdominal trauma (head and abdominal CT versus laparotomy and/or craniotomy)
- Evaluate the stable and alert trauma patient without finding on physical exam who would not routinely undergo radiology imaging
- Help prioritize imaging studies in the multiple-trauma patient
- Help avoid additional imaging in a child with an already low likelihood of intra-abdominal injury

*From Marx JA, Holberger RS. Rosen's emergency medicine: concepts and clinical practice. 5th edition. Mosby; 2002. p. 267–81; with permission.*

how the patient presents neurologically, all efforts should be generated to ensure survival and maintain stable neurologic status within the ED [31].

Examining the brain-injured child involves cranial nerve testing and motor and sensory testing. The evaluation of cranial nerve function is essentially no different from that of the adult. The most important aspect of both motor and cranial nerve evaluation involves ruling out the presence of increased ICP. Common symptoms and signs of increased ICP in infants and children are described as follows:

#### Infants

- Full fontanel
- Split sutures
- Altered states of consciousness
- Paradoxical irritability
- Persistent emesis
- The “sun-setting” sign (inability to open eyes fully)

#### Children

- Headache
- Stiff neck
- Photophobia
- Altered states of consciousness
- Persistent emesis
- Cranial nerve involvement
- Papilledema
- Cushing’s triad (Hypertension, bradycardia and irregular respirations)
- Decorticate or decerebrate posturing

Minor injury to the scalp of infants and children involves the development of three possible injury complexes: caput succedaneum, injury to the connective tissue itself; subgaleal hematoma, injury to the tissue surrounding the skull; and cephalohematoma, a collection of blood under the periosteum.

Skull fractures in children occur in many different configurations [27,30,32]. Linear fractures, the most common type of skull fracture, rarely require therapy and are often associated with good outcomes. Factors favoring a poor outcome include the presence of the fracture overlying a vascular channel, a diastatic fracture, or a fracture that extends over the area of the middle meningeal artery. Diastatic fractures, or defects extending through suture lines, are unlike linear fractures, in that leptomeningeal cysts (growing fractures) may develop at these sites. Fractures of the basilar portions of the occipital, temporal, sphenoid, or ethmoid bones commonly occur in children [33]. The presence of cerebrospinal fluid (CSF), rhinorrhea, and otorrhea has been associated with these injuries. Signs of basilar skull fractures in children are similar to adults and include hemotympanum, seventh and eighth nerve dysfunction, posterior auricular ecchymosis, or Battle’s sign, and raccoon eyes, or the presence of periorbital subcutaneous bleeding [17,26]. As a basic rule, serial examinations are the most reliable indicators of clinical



deterioration [26,29,30,32]. The presence of focality is a reliable indicator of a localized insult, whereas the absence of focality may be misleading. Although there may be few or subtle signs and symptoms of intracranial injury, the following independent predictors have been identified [29]:

- Altered mental status
- Focal neurologic deficits
- Signs of a basilar skull fracture
- Seizure
- Skull fracture

### *Concussion*

Strictly speaking, *concussion* is defined as a brain insult with transient impairment of consciousness. Amnesia is often involved and patients who suffer from concussive insults frequently demonstrate anorexia, vomiting, or pallor soon after the insult. This transitional period is followed by rapid recovery to baseline and if a CT scan of the head is obtained, it is most often normal. Following the Second International Symposium on Concussion in Sport November 2004, concussion was reclassified as simple or complex [34].

- **Simple concussions** are those where loss of consciousness (if any) was less than 1 minute, and symptoms resolve without complication within 7 to 10 days. In such cases, apart from limiting playing and other activities while symptomatic, no further intervention is required during the period of recovery.
- **Complex concussions** include those where there is prolonged loss of consciousness, symptoms or cognitive impairment last longer than 7 to 10 days, or there is a history of multiple concussions. In these cases, return to play should be managed by a multidisciplinary team, and formal neuropsychological testing (testing of attention, memory, and so forth) should be considered.

Since Saunders and Harbaugh [35] first described it in 1984, second-impact syndrome has gained much attention and has led to strict “return-to-play” guidelines for athletes who have suffered a head injury. Second-impact syndrome has been defined as an injury in which “an athlete who has sustained an initial head injury, most often a concussion, sustains a second head injury before symptoms associated with the first have fully cleared” [36]. Given that this can ultimately lead to death, the return-to-play guidelines require strict adherence. When a player shows ANY symptoms or signs of a concussion:

1. The player should **NOT** be allowed to return to play in the current game or practice.
2. The player should not be left alone, and regular monitoring for deterioration is essential over the initial few hours following injury.
3. The player should be medically evaluated following the injury.
4. Return to play must follow a medically supervised stepwise process.

In contrast to concussions, contusions are often the result of coup and contrecoup forces at work. They may not be associated with any loss of consciousness at the time of insult. Patients often present with associated symptoms such as altered level of consciousness, severe headache, vomiting, or focal deficits on neurologic assessment. These injuries are clearly demonstrable on CT.

Traditional teaching regarding the development of epidural hematomas involves the typical triad of head injury followed by a lucid interval, followed by rapid deterioration as intracranial hemorrhage worsens. Unfortunately, in contrast to the adult, pediatric epidural hematomas may be the result of venous bleeding, which predisposes them to a subtle and more subacute presentation over days. In any event, epidural hematomas are associated with a high incidence of overlying skull fractures (60% to 80% of cases).

Special attention to the infant or toddler should be made to rule out the presence of subdural hematomas [26,30]. This clinical scenario is most often secondary to rupture of bridging veins and is rarely associated with the presence of overlying fractures (<30%). Subdural hematomas most commonly occur in patients younger than 2 years of age, with 93% of cases involving children younger than 1 year. Chronic subdural hematomas are most often encountered in patients who have been subjected to what has been named "shaken baby syndrome." This clinical complex involves forcible shaking of the child with acceleratory and deceleratory forces impacting the cranial vault. Twenty-two percent of abused children have central nervous system (CNS) injuries. Patients will present with nonspecific findings, such as vomiting, failure to thrive, change in level of consciousness, or seizures. Retinal hemorrhages are present in 75% of cases, and all patients should have careful funduscopic examinations to rule out the presence of these pathognomonic findings. Left to their own development, the worst cases may actually present with signs of increased ICP. Retinal hemorrhages are not observed in children with mild-to-moderate trauma from other causes and are not associated with a prior history of CPR; the presence of retinal hemorrhages suggests child abuse.

### *Radiology*

*Skull films.* With the advent of multislice CT scanners, the number of skull radiographs being done to rule out skull fractures in children has decreased dramatically. That being said, the presence of a skull fracture on a plain radiograph is one of the strongest predictors for intracranial injury in children younger than 2 [29,37]. Because of this, skull films still may play a role in the evaluation of head trauma in the infant and young child. This is not to say that skull radiography should take the place of CT scanning, but that under the right circumstances the higher radiation and sedation complications that come with CT scans could be avoided without compromising patient outcome [37]. Brenner and colleagues [38] estimated that for every 1500 head CTs done in children younger than 2, one lethal malignancy is directly related to the radiation from the CT. Previous studies have evaluated the

utility of skull radiography versus CT scanning in the evaluation of pediatric head injury. It is universally understood that in any patient with signs and/or symptoms of intracranial injury, CT is the test of choice. In 2001, it was proposed that in a child younger than 2 without symptoms of brain injury but at some risk for skull fracture (eg, presence of scalp swelling), skull radiography may be of some utility [37]. Most clinicians agree that at present, firm indications for skull films alone include the skeletal survey involved with the evaluation of child abuse, establishment of a functioning ventricular peritoneal shunt, penetrating wounds of the scalp, the suspicion of foreign bodies underlying scalp lacerations, or for screening a child younger than 2 thought to have a fracture in the absence of signs or symptoms of brain injury.

*CT of the head.* There has been a considerable amount of research on the indications and relative value of CT scanning in the pediatric head-injured patient. A large study evaluated children between the ages of 2 and 17 years with loss of consciousness and GCS scores of 15 after mild head injury [39]. The children were grouped according to physical examination findings, neurologic status, and whether the head injury was isolated or nonisolated. Patients with obvious skull fractures were excluded. Two variables were highly associated with the presence of intracranial hemorrhage: the presenting neurologic status and presence of multiple injuries. None of the 49 neurologically normal children with isolated head injury had intracranial hemorrhages. All patients with intracranial hemorrhages were noted to have other traumatic insults on physical examination. The authors concluded that after isolated head injury with loss of consciousness, children older than 2 years who were neurologically normal may be discharged without a CT scan after careful physical examination alone. Other studies contradict these findings, establishing a clear association with parenchymal injury and loss of consciousness [29,37,40,41]. At present, recommendations for CT scanning include altered mental status, focal neurologic deficit, signs of a basilar skull fracture, seizure, and a skull fracture or injury patterns that are the result of major forcible insults [29,37]. Special consideration must be taken with children younger than 1 year. These patients challenge the clinician since their neurologic milestones are harder to evaluate. Within this age group any loss of consciousness, protracted vomiting, irritability or poor feeding, or suspicion of abuse would mandate CT scanning.

The infant with minor closed head injury has recently been studied. In a series of 608 children younger than 2 years who underwent CT scanning, a subset of 92 infants younger than 2 months was further scrutinized. The presence of a significant scalp hematoma was highly correlative (77% of subjects with intracranial injury) with underlying parenchymal brain injury. The authors recommend that radiographic imaging not only be directed at asymptomatic infants, but also at those asymptomatic infants with significant scalp hematomas [42].

Recently, the Pediatric Emergency Care Applied Research Network prospectively enrolled 42,495 children who had head trauma and a GCS of 14-15 [43]. The goal was to derive and validate clinical decision rules for obtaining head CT in children less than 2 years old and children greater 2 years with mild head trauma. The results should be available by late 2007–2008.

### *Cervical spine injury*

#### *Perspective*

In the United States more than 1100 children sustain spinal injury annually, leading to an annual cost exceeding \$4 billion [44,45]. Cervical injury patterns vary with the age of the patient. It has been reported that 1% to 10% of all spine injuries are in the pediatric age group and that 60% to 80% of all pediatric vertebral injuries are in the cervical spine [46–48]. Fractures below the C3 level account for only 30% of spinal lesions among children younger than 8 years, dramatically different from those patterns seen in the adult population. Likewise, spinal cord injury without radiographic abnormality (SCIWORA) has been found in 30% to 40% of spinal cord injuries in this same age group [48–51].

#### *Imaging the pediatric cervical spine*

A prospective study done in 3065 patients younger than 18 proved that when using their criteria for obtaining cervical spine imaging in pediatric blunt trauma, there was a 100% sensitivity and a 100% negative predictive value. Criteria for obtaining imaging included midline cervical tenderness, altered level of alertness, evidence of intoxication, neurologic abnormality, and the presence of a painful distracting injury. The authors urged caution in using the criteria in children younger than 2 years old, as this age group was not well represented (88 of 3065) [52]. Caution should also be used in patients with congenital or acquired abnormalities (eg, Down syndrome, juvenile rheumatoid arthritis, prior fracture) [50]. When indicated, radiographic evaluation should routinely consist of three views: a cross-table lateral view, an anteroposterior view, and an open-mouth view to help visualize the odontoid process of C1. With these three plain film views of the cervical region, the sensitivity for detecting cervical fractures is 89% and the negative predictive value of these three views adequately done is nearly 100% [53]. Interpretation of plain cervical spine films in children may be challenging because of the anatomic changes that occur with growth (Box 8). In addition, pseudosubluxation of C2 on C3 is common in children up to adolescence, occurring in approximately 40% of patients [54]. The EP distinguishes between pseudosubluxation and true subluxation by the posterior cervical line or spinolaminar line, also known as the *line of Swischuk*. A line is drawn from the anterior cortical margin of the spinous process of C1 down through the anterior cortical margin of C3. If this line at C2 crosses the anterior cortical margin of the

**Box 8. Anatomic differences in the pediatric cervical spine**

- Relatively larger head size, resulting in greater flexion and extension injuries
- Smaller neck muscle mass with ligamentous injuries more common than fractures
- Increased flexibility of interspinous ligaments
- Infantile bony column can lengthen significantly without rupture
- Flatter facet joints with a more horizontal orientation
- Incomplete ossification making interpretation of bony alignment difficult
- Basilar odontoid synchondrosis fuse at 3 to 7 years of age
- Apical odontoid epiphysis fuse at 5 to 7 years of age
- Posterior arch of C1 fuses at 4 years of age
- Anterior arch fuses at 7 to 10 years of age
- Epiphyses of spinous process tips may mimic fractures
- Increased preodontoid space up to 4 to 5 mm (3 mm in an adult)
- Pseudosubluxation of C2 on C3 seen in 40% of children
- Prevertebral space size may change because of variations with respiration

spinous process at C2 or is off by less than 2 mm and no fractures are visualized, then the patient has pseudosubluxation versus true subluxation of the ligaments at that level (Fig. 2) [55,56].

An important criterion for radiographic clearing of the cervical spine is complete visualization of all seven cervical vertebral bodies down to, and including, the C7 to T1 interface. The predental space should not exceed 4 to 5 mm in children younger than 10 years, and the prevertebral soft-tissue space should not be greater than normal. The 4 cervical radiographic lines should be evaluated, and the atlanto-occipital alignment should be assessed for dislocation in this region (see Fig. 2).

Other imaging modalities that can be used to delineate cervical fractures include thin-section CT and MRI.

*Cardiothoracic injury**Perspective*

The vast majority of serious chest injuries in children (83%) are the result of blunt trauma [8,57]. Most are the result of MVCs with the remainder secondary to bicycle crashes. Isolated chest injury is a relatively infrequent occurrence when considering the typical mechanisms of blunt trauma in the pediatric patient. The presence of significant chest injury greatly enhances

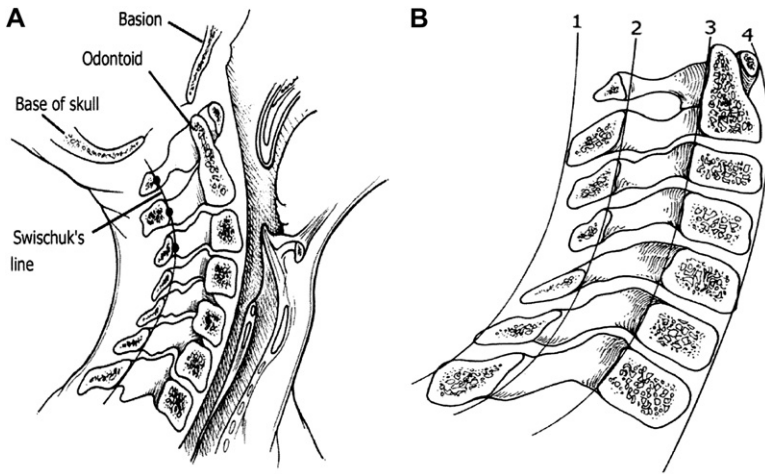


Fig. 2. (A) The spinolaminar line (Swischuk's line) used to determine the presence of pseudo-subluxation of C2 on C3. (B) Normal relationships in the lateral aspect of the cervical spine. 1 = spinous processes, 2 = spinolaminar line, 3 = posterior vertebral body line, and 4 = anterior vertebral body line. (Reprinted from Copley LA, Dormans JP. Cervical spine disorders in infants and children. *J Am Acad Orthop Surg* 1998;6:207; with permission.)

the potential for multisystem trauma mortality by a factor of 10. Sequelae of blunt injury include rib fractures and pulmonary contusion (50%), pneumothorax (20%), and hemothorax (10%).

Overall mortality is nearly equivalent for blunt versus penetrating trauma. Children subjected to penetrating trauma, unlike the injuries associated with blunt trauma, will often die from the primary insult itself. Penetrating trauma accounts for only 15% of thoracic insults in children [58–60]. Our nationwide fascination with the use of firearms has resulted in an increasing incidence of penetrating trauma with the child as victim. Specific clinical patterns should alert the clinician to the potential for concurrent abdominal and thoracic injury. Any patient with penetrating trauma at or below the level of the sixth rib will fall into this category.

### *Principles of disease*

It is important to understand the physiology of pediatric respiration when considering the potential for early decompensation. Infants and young children are preferential diaphragm breathers and any impairment of diaphragmatic mobility will compromise ventilation. The presence of gastric distention will elevate the diaphragm and severely lessen the vital capacity of a child. In addition, the particular types of muscle fibers involved in the diaphragm of infants and young children predispose to the sudden development of apnea when fatigued. Most importantly, the presence of adequate oxygenation in the pediatric patient does not always ensure sufficiency of ventilation. It is important to rely upon auscultatory and other physical findings rather than simple measurements of oximetry.

Infants and children are anatomically protected against blunt thoracic cage trauma because of the compliance of the rib cage [61]. Compressibility of the rib cage will dissipate the force of impact, which will lessen the likelihood of bony injury. These protective mechanisms may also mask fairly complex pediatric thoracic insults. The compliance of the rib cage will allow significant injury to occur with little apparent external signs of trauma. Multiple rib fractures are a marker of serious injury in children, with child abuse being the most likely etiology and the mortality rate exceeding 40%. In addition, the pediatric mediastinum is mobile, which favors the development of rapid ventilatory and circulatory collapse in the presence of a tension pneumothorax.

### *Pneumothorax*

The development of a traumatic pneumothorax is commonly associated with significant pulmonary injury [58]. In contrast to spontaneous pneumothoraces, these insults will not resolve spontaneously and are often associated with the presence of a hemothorax.

Signs and symptoms include external evidence of chest trauma such as abrasion, contusion, or ecchymosis; tachypnea; respiratory distress; hypoxemia; and chest pain. Decreased breath sounds may not be appreciated in children with pneumothoraces because of the wide transmission of breath sounds in the chest and upper abdomen.

Management of a simple pneumothorax noted on chest radiograph includes the placement of a large-caliber, laterally placed chest tube or close observation. Chest tube size can be estimated as 4 times the endotracheal tube size or can be found on a length-based resuscitation tape. Also, any patient with a pneumothorax who will be undergoing mechanical ventilation requires the placement of a chest tube. In the most conservative of scenarios, small (<20%), simple pneumothoraces that are not under tension, and in children who will not be mechanically ventilated, may be observed carefully for extended periods, with treatment of 100% oxygen supplementation and reassessment by repeat chest radiographs at selected intervals.

### *Tension pneumothorax*

The development of pulmonary air leaks that occur in a one-way valve arrangement favors the development of a tension pneumothorax. Increasing amounts of free air within the pleural cavity will cause the mediastinal structures to shift toward the opposite side, compromising cardiac output. The final common pathway involves hypoxia, hypotension, and refractive cardiogenic shock. Most patients will present with severe respiratory distress, decreased breath sounds, and a shift in the point of maximal cardiac impulse. In the worst scenario, the mediastinum shift will force contralateral tracheal deviation and distention of the neck veins. In pediatric patients, signs of tension pneumothorax are often subtle. A short neck and increased soft tissue may make detection of tracheal deviation difficult. Therefore, the evaluation of pediatric patients for tension pneumothorax should consider

skin signs and profound tachycardia, suggesting shock. The EP should consider the diagnosis of tension pneumothorax, and if detected or strongly suspected, should immediately treat the patient. Without adequate decompression, circulatory collapse and hypotension will occur.

The treatment for a tension pneumothorax involves rapid evacuation of the trapped air. In the out of hospital setting treatment includes needle thoracostomy placed in the second intercostal space within the midclavicular line or possibly in the fourth intercostal space anterior to the axillary line (nipple line). The needle should be placed above the rib margin to avoid injuring the intercostal vessels. In the ED, definitive treatment involves the use of a large-caliber thoracostomy tube that will favor drainage of the tension pneumothorax and any accompanying hemothorax.

### *Hemothorax*

Significant bleeding may occur when injury is directed toward the intercostal, internal mammary vessels or lung parenchyma. Without an upright chest film, it is difficult to quantify the degree of bleeding on plain radiographs. Development of a massive hemothorax is rare in children and is most associated with severe impact, such as seen in high-velocity MVCs, falls from extreme heights, or the use of high-powered firearms. These injuries must undergo rapid evaluation and treatment. Clinically, patients will present with decreased breath sounds and dullness to percussion on the affected side. A pneumothorax may coexist with a hemothorax. The pediatric patient may present with early or late signs of hypovolemic shock.

Any alteration in cardiovascular sufficiency should be treated with rapid replacement of fluids with isotonic crystalloid solutions. One must also prepare for transfusion with the institution of red blood cell (RBC) replacement as necessary. Patients who present with profound shock may receive either type-specific or O-negative blood, while cross-matched blood may be used for more stable patients. The amount of blood that is salvaged from the chest tube should be quantified to help determine the need for RBC replacement. Many centers have the capability to salvage blood from hemothoraces and reinfuse, using an autotransfuser. As in all cases of trauma, initial measurement of the hemoglobin is often unreliable for estimating the amount of blood loss, since an adequate time interval for equilibration may not yet have passed.

The treatment of hemothorax includes a tube thoracostomy. The tube needs to be large enough to occupy most of the intercostal space and should be placed laterally and directed posteriorly. As in all interventions, repeat chest radiographs should be obtained to confirm positioning and document improvement in lung expansion. Indications for thoracotomy include evacuated blood volumes exceeding 10 to 15 mL/kg of blood, blood loss that exceeds 2 to 4 mL/kg/hr, or continued air leak. ED thoracotomy is reserved for patients suffering penetrating trauma who deteriorate to cardiopulmonary failure despite maximal resuscitation in the out of hospital setting or



ED. The EP will often be able to stabilize the patient with RBC replacement until surgical intervention is achieved [59–61].

### *Cardiac and vascular injuries*

Fortunately, injuries to the heart and large vessels are uncommon in children [62–65]. The most common traumatic cardiovascular injury sustained by children is myocardial contusion. Patients will often present with chest wall tenderness or may have a complaint of generalized chest pain. Tachycardia is the most common finding. Elevation of myocardial enzymes may be diagnostic. Patients with myocardial contusions should be monitored closely for the development of both dysrhythmias and impaired myocardial function; however, in most cases of myocardial contusion, there are no long-term sequelae. The most life-threatening scenario involving the cardiac structures is the development of cardiac tamponade. Extravasated blood will fill the pericardial space and impair cardiac filling during diastole. Tamponade is most often the result of a penetrating wound. Firearm insult will often cause sudden death, and blunt trauma rarely results in the development of cardiac tamponade. Clinically, patients will present with tachycardia, distant heart sounds, narrow pulse pressure, jugular venous distention, and pulsus paradoxus. In the scenario of profound hypovolemia, venous distention will be absent. The final common pathway involves the development of pulseless electrical activity (PEA).

In cardiac and vascular injuries, the ECG may demonstrate anything from tachycardia with low voltage (pericardial tamponade) to findings consistent with acute myocardial infarction (ST elevation). In the subacute scenario, echocardiography will often make the diagnosis. Bedside transthoracic echocardiography will clearly define the degree of pericardial effusion present, as well as the significance of any diastolic dysfunction present. A simple single subxyphoid view during the FAST exam provides the EP with an excellent view of the pericardial sac and heart. Pericardiocentesis may be both diagnostic and therapeutic. Definitive treatment involves drainage of the fluid from the pericardial sac. In certain situations, the amount of pericardial blood and clot will necessitate the performance of a thoracotomy to adequately evacuate the pericardium.

### *Commotio cordis*

Commotio cordis is a disorder described in the pediatric population that results from sudden impact to the anterior chest wall (such as seen in baseball injuries) that causes cessation of normal cardiac function [57,65,66]. The patient may have an immediate dysrhythmia or ventricular fibrillation that is refractory to resuscitation efforts.

Significant morbidity and mortality are associated with this disorder, and, although most recover completely, some patients require extended treatment with antiarrhythmic agents, cardiac pacemaker placement, inotropic agents,

or intra-aortic balloon pumps. Cardiogenic shock and death are often frequent outcomes of patients, despite maximal therapeutic interventions [57,66].

### *Abdominal injuries*

Serious abdominal injury accounts for approximately 8% of admissions to pediatric trauma centers [67]. Abdominal trauma is the third leading cause of pediatric traumatic death after head and thoracic injuries and is the most common cause of unrecognized fatal injury in children. Pediatric abdominal trauma results from blunt causes in 85% of cases, and penetrating trauma accounts for the remaining 15%. Of patients presenting primarily for other associated injuries, 9% die from abdominal trauma associated with these injuries.

Blunt trauma related to MVCs causes more than 50% of the abdominal injuries in children and is also the most lethal. “Lap-belt” injury including small bowel injury and Chance fractures occurs in approximately 5% to 10% of restrained children involved in MVCs [68–70]. Another common cause of abdominal injury involves bicycle crashes. Handlebar injuries represent a serious cause of injury and subsequent hospitalization for the pediatric population, with those requiring admission having a mean hospital stay exceeding 3 weeks. Often the effects of bicycle injuries may not be seen on initial presentation, with the mean elapsed time to onset of symptoms being nearly 24 hours.

Sports-related injuries are another common cause of pediatric abdominal trauma. Sports-related injuries are most commonly associated with isolated organ injury as a result of a blow to the abdomen. At particular risk are the spleen, kidney, and intestinal tract in children [71]. Finally, significant abdominal injury occurs in only about 5% of child abuse cases, but it is the second most common cause of death in these cases.

The anatomy of the child lends special protection from some abdominal injury patterns and predisposes the patient to other types of injuries in both blunt and penetrating abdominal trauma [71]. Children have proportionally larger solid organs, less subcutaneous fat, and less protective abdominal musculature than adults and therefore relatively more solid organ injury from both blunt and penetrating mechanisms. Children also have relatively larger kidneys with fetal lobulations that predispose them to renal injury. The child has a fairly flexible cartilaginous ribcage that allows for significant excursion of the lower chest wall, permitting compression of the internal organs. The combination of these factors provides the basis for the differences in abdominal injury patterns seen between children and adults.

Blunt abdominal trauma often presents as a part of the multitraumatized pediatric patient. In the child, history is often limited, traditional signs of decompensation seen in adults are often not as evident, and physical examination can be difficult [71]. Therefore, subtle, early abdominal findings may be overlooked, leading to significant morbidity and mortality. The history and

examination of young children who have suffered trauma is challenging, as it may be difficult to know if the child hurts “all over” or has focal findings. The EP may use distraction with toys, lights, or keys to get the child’s mind off the examiner and onto the distraction; in this way, areas of tenderness may be located.

Signs and symptoms of abdominal injury in children include tachypnea from impaired diaphragmatic excursion, abdominal tenderness, ecchymosis, and signs of shock. Abdominal distension is a common nonspecific later finding, often the result of air swallowing subsequent to a painful event. Children with hepatic and splenic injuries may have trouble localizing their pain. Thus, any abdominal tenderness on examination should prompt evaluation of the abdomen. Vomiting is usually a late sign or one associated with duodenal hematoma or traumatic pancreatitis. Signs of small bowel injury may be delayed and only noted clinically with serial examinations. Pelvic bone stability and a rectal examination looking for signs of urethral injury (rare) in boys or blood in the stool (both girls and boys) needs to be performed in all cases of serious trauma.

Even minor falls can result in significant splenic injury, but with only minimal findings on examination. Repeated examination, prolonged observation, and close attention to vital signs are warranted. Any child with a clinically suspicious abdominal examination should be evaluated further with additional radiologic and laboratory studies.

In patients with suspect abdominal injury or with mechanisms of possible injury, management and resuscitation must be rapid. Children, because of fear and pain, can compound the difficulties in the management of serious penetrating or blunt abdominal trauma. Children tend to distend the stomach greatly with ingested air that can then decrease the diaphragmatic excursion related to overdistention of the abdomen. This can compromise respiratory efforts, and therefore early decompression via nasogastric or orogastric tube insertion should be considered. Children with a stable pelvis and who are not at risk of urethral trauma should have a urinary catheter inserted to decompress the bladder, evaluate for the presence of urinary retention, and examine for the presence of blood in the urine [72]. Also, before any invasive evaluation of the abdomen, such as DPL, the bladder should be decompressed to prevent accidental laceration during the procedure.

### *Radiology*

Because pediatric patients suffer more from injury to the spleen, liver, kidneys, and the gastrointestinal tract, CT of the abdomen can provide high sensitivity and specificity for identification of these injuries while being relatively noninvasive [23]. That being said, there are adverse effects related to CT in pediatric patients. Because of delays in evaluation, difficulty with administration, and risk for aspiration, the necessity of using oral contrast media in CT is often criticized. The radiation that accompanies CT is also of great concern. Brenner and colleagues [38] estimated that the total

number of deaths attributable to 1 year of CT examinations in individuals who were less than 15 years of age at the time of examination is approximately 170 from head CT's and 310 from abdominal CT's [38]. In a 1 year-old child, the lethal malignancy risk from 1 abdominal CT is approximately 1 in 550. It is clear that CT-related malignancy is a major issue. Finding other modalities for predicting and evaluating the pediatric abdomen are needed to reduce that risk.

Another useful procedure in the acutely traumatized pediatric patient is the FAST exam. When used by a properly trained EP, the FAST evaluation has the potential to provide sensitive and specific identification of intraperitoneal hemorrhage without invasive measures. The FAST exam does not have the ability to reliably detect specific organ injuries. Holmes and colleagues [73] conducted a prospective, observational study of children with a mean age of 9.5 ( $\pm$  4.7 years) with blunt trauma who underwent abdominal ultrasound in the ED ( $n = 224$ ). They found that of the 13 patients who presented with hypotension, ultrasound had 100% sensitivity, specificity, positive predictive value and negative predictive value for detecting intra-abdominal injury-related hemoperitoneum. The sensitivity and specificities for all 224 patients were 82% and 95% respectively [73]. Sou-dack and colleagues [74] retrospectively reviewed the medical records and sonographic examinations of 313 patient ages 2 months to 17 years (mean, 7.1 years) who sustained multiple traumatic injuries and had FAST as their initial screening examination. There were 275 patients who had a negative FAST result; 73 subsequently had clinical signs of intra-abdominal injury and underwent CT evaluation. Only 3 of the 73 were positive for parenchymal injury and were managed nonoperatively. They concluded that in their institution, the sensitivities and specificities of the FAST evaluation for the pediatric age group was 92.5% and 97.2%, respectively [74]. The aforementioned studies do have some limitations but prove that the use of the FAST shows promise as an initial screening tool in the pediatric age group.

Although radiological evaluation can provide important diagnostic information in the pediatric patient with possible abdominal trauma, any patient with unstable vital signs should not be delayed in receiving operative intervention. Children with persistent or recurrent hypotension, continued abdominal pain, or persistent abdominal distention should have expedient evaluation by a surgeon [73,75,76].

#### *Traumatic diaphragmatic hernia*

Children involved in MVCs who are wearing lap belts are predisposed to the development of diaphragmatic herniation [68,77]. Mechanisms of traumatic diaphragmatic hernia involve sudden compressive forces exerted over the abdomen causing an increase in the intra-abdominal pressure and resulting in tearing of the diaphragm. Patients may initially present in stable condition with the degree of respiratory distress directly proportional to the amount

of abdominal contents that protrude into the pulmonary space. Presence of ecchymosis across the abdomen and flanks, which may be secondary to lap belt compression, should alert the clinician to the possibility of diaphragmatic hernia, other intra-abdominal injuries (small bowel injury), and the possibility of associated thoracic spinal insults, such as Chance fractures [68,70]. Unfortunately, traumatic diaphragmatic herniation is one of the most commonly missed injuries and has been reportedly missed in 12% to -66% of cases [78].

Diagnosis is often difficult and although various imaging modalities are available to assist in making the diagnosis, there is no one highly sensitive test. In a retrospective chart review of a mostly adult population, Mihos and colleagues [78] reported an 80% sensitivity in diagnoses using CT alone. That same article reported that the sensitivity of CT ranges from 33% to 83%. This injury can be missed even after undergoing a laparotomy, stressing the difficulty in making the diagnosis.

Initial management for these patients involves placement of a nasogastric tube to decompress the stomach and augment diagnostic imaging. In cases of severe respiratory distress, intubation is indicated. Surgery will be required for repair of the injury.

### *Splenic injury*

Injuries to the spleen are in the largest proportion of pediatric abdominal trauma. Children involved in MVCs, sudden deceleration injuries, and contact sports-related injuries may suffer from splenic trauma. Typical findings include left upper quadrant abdominal pain radiating to the left shoulder. The abdominal examination may show evidence for peritoneal irritation in the left upper quadrant of the abdomen. Patients may be hemodynamically stable or, after significant splenic rupture or laceration, may be persistently hypotensive or in fulminant cardiovascular collapse. A surgeon should evaluate all patients with suspected splenic injury. Stable patients may undergo CT for radiologic evaluation. A FAST exam may reveal associated intraperitoneal hemorrhage, but does not rule out a splenic injury if negative. Most often, with minor splenic trauma, bleeding will spontaneously be controlled without operative intervention. Because of the desire for splenic salvage to maintain immunocompetency, an injured spleen is often left in place as long as the patient can be adequately resuscitated with crystalloid and blood products. In cases with a contained splenic subcapsular hematoma, bleeding may present days later. Patients with splenic injury should be admitted to the hospital for close observation and repeated examinations.

### *Liver injury*

The liver is the second most commonly injured solid organ in the pediatric patient with abdominal trauma. It is the most common cause of lethal hemorrhage, carrying a mortality of 10% to 20% in severe liver injury. Mechanisms of injury causing splenic injury may also cause liver trauma. Tenderness on palpation of the right upper quadrant of the abdomen along

with the complaint of abdominal pain in this region or in the right shoulder are signs of possible liver injury. Patients managed conservatively often do well; however, those that are initially treated as such and then go on to require delayed laparotomy often have significant morbidity and mortality. Therefore, close observation in the hospital, serial abdominal examinations, and serial hemoglobin should be performed.

### *Renal injury*

The kidney is less susceptible to trauma from forces applied to the anterior abdomen, but is often injured in the multitrauma pediatric patient [7]. Because this organ is retroperitoneal, complaints of abdominal pain are often less obvious and are more diffuse. Often dull back pain, ecchymosis in the costovertebral region, or hematuria are the only clues to renal injury. Renal ultrasound and CT may be used in the stable patient to assess the degree of renal involvement [41,79,80]. Other organs such as the pancreas and gastrointestinal tract are less frequently injured in the pediatric patient.

### *Penetrating injury*

Penetrating wounds to the abdomen usually require rapid evaluation by a surgeon and in some cases, operative intervention. The role of DPL in the management of pediatric trauma is controversial and seems to be fading out of practice as the FAST exam continues to gain acceptance. DPL provides a rapid, nonspecific evaluation of possible intraperitoneal hemorrhage. Certainly patients who remain unstable despite fluid resuscitation may be candidates for DPL if they are too unstable for CT and there are multiple potential sites of blood loss. An important role for DPL is in the setting of an underlying small bowel injury (SBI). In some patients with SBI, CT findings of free fluid may be improperly ascribed to underlying splenic bleeding. Finally, DPL may be considered in the operating room for patients undergoing emergent craniotomy, when adequate evaluation of the abdomen cannot take place because of the time urgency required for intervention for head injury. If the wound appears superficial and does not appear to travel below the abdominal musculoaponeurotic layer, local exploration by an experienced surgeon may be useful [17].

### *Disposition*

Finally, the EP must decide to admit the pediatric trauma patient, transfer the patient to a tertiary care facility, or discharge the patient. The decision for admission should be based on consultation with the surgeon and the patient's primary care physician. Infants and children who are moderately to severely injured have improved outcomes in a pediatric intensive care unit (PICU) versus an adult ICU; therefore, the primary role of the EP

**Box 9. Indications for surgery**

- Hemodynamic instability despite maximal resuscitative efforts
- Transfusion of greater than 50% of total blood volume
- Radiographic evidence of pneumoperitoneum, intraperitoneal bladder rupture, grade V renovascular injury
- Gunshot wound to the abdomen
- Evisceration of intraperitoneal or stomach contents
- Signs of peritonitis
- Evidence of fecal or bowel contamination on diagnostic peritoneal lavage

would be to evaluate and stabilize the patient before admission to a PICU or before transfer to a tertiary care facility. Before transport, it is vital that the child be appropriately stabilized and that the EP communicates directly with the accepting physician at the transfer facility.

Indications for admission are many, but the main principle is to admit patients requiring ongoing monitoring for deterioration or complications of their injuries. Indications for surgery are outlined in (Box 9). Whatever the surgical preference within a health care facility, it is most important to establish a protocol for approaching these challenging patients. Of course, patients who remain hypotensive after adequate crystalloid infusion are candidates for early operative exploration. In addition, children with suspected physical injury from child abuse may be admitted for their protection as well as for medical treatment.

**Summary**

Trauma remains the leading cause of death in children nationwide. Proper management of the pediatric trauma patient involves most of the components of standard trauma protocols. By paying strict attention to the anatomic and physiologic differences in children, the clinician will be ensured the best patient outcomes.

**References**

- [1] Jaffe D. Emergency management of blunt trauma in children. *N Engl J Med* 1991;324:1477–82.
- [2] Miniño A, Heron M, Smith B, et al. Deaths: final data for 2004. National vital statistics reports. Hyattsville (MD). National Center for Health Statistics.
- [3] King DR. Trauma in infancy and childhood: initial evaluation and management. *Pediatr Clin North Am* 1985;32:1299–310.

- [4] Langlois JA, Rutland-Brown W, Thomas KE. Traumatic brain injury in the United States: emergency department visits, hospitalizations, and deaths. Atlanta (GA): Centers for Disease Control and Prevention, National Center for Injury Prevention and Control; 2006.
- [5] Peclet MH, Newman KD, Eichelberger MR, et al. Patterns of injury in children. *J Pediatr Surg* 1990;25:85–90.
- [6] Sieben RL, Leavitt JD, French JH. Falls as childhood accidents: an increasing urban risk. *Pediatrics* 1971;47:886.
- [7] Ablu-Jaude WA. Indicators of genitourinary tract injury or anomaly in cases of pediatric blunt trauma. *J Pediatr Surg* 1996;31:86.
- [8] Corey TS. Infant deaths due to unintentional injury: an 11-year autopsy review. *Am J Dis Child* 1992;146:968–71.
- [9] Schafer I, Barkmann C, Riedesser P, et al. Posttraumatic syndromes in children and adolescents after road traffic accidents—a prospective cohort study. *Psychopathology* 2006;39(4):159–64.
- [10] Gausche M, Lewis RJ, Stratton SJ, et al. Effect of out-of-hospital pediatric endotracheal intubation on survival and neurological outcome: a controlled clinical trial. *JAMA* 2000;283:783–9.
- [11] Part 12: Pediatric Advanced Life Support Circulation 112: IV-167-187IV-; published online before print as doi:10.1161/CIRCULATIONAHA.105.166573.
- [12] Waltzman ML, Mooney DP. Major trauma. In: Fleisher GR, Ludwig S, Henretig FM, editors. *Textbook of pediatric emergency medicine*. 5th edition. Philadelphia: Lippincott Williams & Wilkins; 2006. p. 1339–48.
- [13] Kanter RK, Zimmerman JJ, Strauss RH, et al. Pediatric emergency intravenous access. Evaluation of a protocol. *Am J Dis Child* 1986;140:132–4.
- [14] Hodge D, Delgado-Paredes C, Fleisher G. Intraosseous infusion flow rates in hypovolemic “pediatric” dogs. *Ann Emerg Med* 1987;16:305–7.
- [15] Fiser DH. Intraosseous infusion. *N Engl J Med* 1990;322:1579–81.
- [16] Banerjee S, Singhi SC, Singh S, et al. The intraosseous route is a suitable alternative to intravenous route for fluid resuscitation in severely dehydrated children. *Indian Pediatr* 1994;31:1511–20.
- [17] American college of surgeons. *Advanced Trauma Life Support (ATLS) student course manual*. 7th edition. Chicago: American College of Surgeons; 2004.
- [18] Furnival RA. Delayed diagnosis of injury in pediatric trauma. *Pediatrics* 1996;98:56–62.
- [19] Brown K, Bocoek J. Update in pediatric emergency resuscitation. *Emerg Med Clin North Am* 2002;20(1):1–26.
- [20] Holmes JF, Sokolove PE, Brant WE, et al. Identification of children with intraabdominal injuries after blunt trauma. *Ann Emerg Med* 2002;39:500–9.
- [21] Isaacman DJ. Utility of routine laboratory testing for detecting intra-abdominal injury (IAI) in the pediatric trauma patient. *Pediatrics* 1993;92:691–4.
- [22] Zehtabchi S, Sinert R, Goldman M, et al. Diagnostic performance of serial haematocrit measurements in identifying major injury in adult trauma patients. *Injury* 2006;37:46–52.
- [23] Stanescu LA, Gross JA, Bittle M, et al. Imaging of blunt abdominal trauma. *Semin Roentgenol* 2006;41(3):196–208.
- [24] Saladino RA, Lund DP. Abdominal trauma. In: Fleisher GR, Ludwig S, Henretig FM, editors. *Textbook of pediatric emergency medicine*. 5th edition. Philadelphia: Lippincott Williams & Wilkins; 2006. p. 1339–48.
- [25] Rose JS. Ultrasound in abdominal trauma. *Emerg Med Clin North Am* 2004;22(3):581–9.
- [26] Theissen ML, Woolridge DP. Pediatric minor closed head injury. *Pediatr Clin North Am* 2006;53:1–26.
- [27] Lescholier I. Blunt trauma in children: causes and outcomes of head vs extracranial injuries. *Pediatrics* 1993;91:721–5.



- [28] Agran RA, Dunkle DE. Motor vehicle occupant injuries to children in crash and non crash events. *Pediatrics* 1982;70:993.
- [29] Quayle KS, Jaffe DM, Kuppermann N, et al. Diagnostic testing for acute head injury in children: when are head computed tomography and skull radiographs indicated? *Pediatrics* 1998;99(5):1-8.
- [30] Ghajar J. Management of pediatric head injury. *Pediatr Clin North Am* 1992;39:1093-125.
- [31] Lieh-Lai MW. Limitations of the Glasgow Coma Scale in predicting outcome in children with traumatic brain injury. *J Pediatr* 1992;120:195-9.
- [32] Hennes H. Clinical predictors of severe head trauma in children. *Am J Dis Child* 1988;142:1045-7.
- [33] Kadish HA. Pediatric basilar skull fracture: do children with normal neurologic findings and no intracranial injury require hospitalization? *Ann Emerg Med* 1995;26:37-41.
- [34] McCrory P, Johnston K, Meeuwisse W, et al. Summary and agreement statement of the 2nd international conference on concussion in sport, Prague 2004. *Clin J Sport Med* 2005;15(2):48-55.
- [35] Saunders RL, Harbaugh RE. The second impact in catastrophic contact-sports head trauma. *JAMA* 1984;252:538-9.
- [36] Cantu RC. Second impact syndrome. *Clin Sports Med* 1998;17(1):37-44.
- [37] Schutzman SA, Barnes P, Dunhaim A, et al. Evaluation and management of children younger than two years old with apparently mild head trauma: proposed guidelines. *Pediatrics* 2001;107:983-93.
- [38] Brenner D, Elliston C, Hall E, et al. Estimated risks of radiation-induced fatal cancer from pediatric CT. *AJR Am J Roentgenol* 2001;176(2):289-96.
- [39] Davis RL. Cranial CT scans in children after minimal head injury with loss of consciousness. *Ann Emerg Med* 1994;24:640-5.
- [40] Davis RL. The use of cranial CT scans in the triage of pediatric patients with mild head injuries. *Pediatrics* 1995;95:345.
- [41] Livingston DH. The use of CT scanning to triage patients requiring admission following minimal head injury. *J Trauma* 1991;31:483-7.
- [42] Greenes DS. Clinical indicators of intracranial injury in head-injured infants. *Pediatrics* 1999;104:861-7.
- [43] Kupperman N, Holmes J, Dayan P, et al. Blunt head trauma in the pediatric emergency care applied research network (PECARN). *Acad Emerg Med* 2007;14(5):Suppl. 1.
- [44] Apple JS, Kirks DR, Merten DF, et al. Cervical spine fractures and dislocations in children. *Pediatr Radiol* 1987;17:45-9.
- [45] Chen LS, Blaw ME. Acute central cervical cord syndrome caused by minor trauma. *J Pediatr* 1986;108:96-7.
- [46] Cirak B, Ziegfeld S, Knight V, et al. Spinal injuries in children. *J Pediatr Surg* 2004;39:607-12.
- [47] Reynolds R. Pediatric spinal injury. *Curr Opin Pediatr* 2000;12:67-71.
- [48] Pang D. Spinal cord injury without radiologic abnormality in children, 2 decades later. *Neurosurgery* 2004;55:1325-43.
- [49] Hadley MN, Zabramski JM, Browner CM, et al. Pediatric spinal trauma: review of 122 cases of spinal cord and vertebral column injuries. *J Neurosurg* 1988;68:18-24.
- [50] Hill SA, Miller CA, Kosnik EJ, et al. Pediatric neck injuries: a clinical study. *J Neurosurg* 1984;60:700-6.
- [51] Pang D, Wilberger JE. Spinal cord injury without radiographic abnormalities in children. *J Neurosurg* 1982;57:114.
- [52] Viccellio P, Simon H, Pressman BD, et al, NEXUS Group. A prospective multicenter study of cervical spine injury in children. *Pediatrics* 2001;108(2):E20.
- [53] Mower WR, Hoffman JR, Pollack CV Jr, et al, NEXUS Group. Use of plain radiography to screen for cervical spine injuries. *Ann Emerg Med* 2001;38(1):1-7.
- [54] Cattell HS, Filtzer DL. Pseudosubluxation and other normal variations in the cervical spine in children. *J Bone Joint Surg Am* 1965;47:1295-309.

- [55] Strange GR, editor. *APLS: The pediatric emergency medicine course*. Elk Grove (IL): American academy of pediatrics and American college of emergency physicians; 1998.
- [56] Copley LA, Dormans JP. Cervical spine disorders in infants and children. *J Am Acad Orthop Surg* 1998;6:204-14.
- [57] Maron BJ. Blunt impact to the chest leading to sudden death from cardiac arrest during sports activities. *N Engl J Med* 1995;333:337-42.
- [58] Bender TM. Pediatric chest trauma. *J Thorac Imaging* 1987;2:60.
- [59] Meller JL, Little AG, Shermeta DW. Thoracic trauma in children. *Pediatrics* 1984;74:813.
- [60] Eichelberger MR. Trauma of the airway and thorax. *Pediatr Ann* 1987;16:307.
- [61] Cooper A. Thoracic trauma. In: Barkin RM, editor. *Pediatric emergency medicine: concepts in clinical practice*. St Louis (MO): Mosby; 1992.
- [62] Eshel G. Cardiac injuries caused by blunt chest trauma in children. *Pediatr Emerg Care* 1987;3:96-8.
- [63] Fishbone G, Robbins DI, Osborn DJ, et al. Trauma to the thoracic aorta and great vessels. *Radiol Clin North Am* 1973;11:543-54.
- [64] Tellez DW. Blunt cardiac injury in children. *J Pediatr Surg* 1987;22:1123-8.
- [65] Abrunzo TJ. Commotio cordis: the single most common cause of traumatic death in youth baseball. *Am J Dis Child* 1991;145:1279-82.
- [66] Amerongen RV. Ventricular fibrillation following blunt chest trauma from a baseball. *Pediatr Emerg Care* 1997;13:107-10.
- [67] Schafermeyer RW. Pediatric trauma. *Emerg Med Clin North Am* 1993;11:187.
- [68] Sivit CJ. Safety-belt injuries in children with lap-belt ecchymosis. *AJR Am J Roentgenol* 1991;157:111-4.
- [69] Angran PF, Dunkle DE, Winn DG. Injuries to a sample of seat belted children evaluated and treated in a hospital emergency room. *J Trauma* 1987;27:58.
- [70] Sturm PF. Lumbar compression fractures secondary to lap-belt use in children. *J Pediatr Orthop* 1995;15:521-3.
- [71] Saladino R. The spectrum of liver and spleen injuries in children: failure of the PTS and clinical signs to predict isolated injuries. *Ann Emerg Med* 1991;20:636-40.
- [72] Stalker HP. The significance of hematuria in children after blunt abdominal trauma. *AJR Am J Roentgenol* 1990;154:569-71.
- [73] Holmes JF, Brant WE, Bond WF, et al. Emergency department ultrasonography in the evaluation of hypotensive and normotensive children with blunt abdominal trauma. *J Pediatr Surg* 2001;36(7):968-73.
- [74] Soudack M, Epelman M, Maor R, et al. Experience with Focused Abdominal Sonography for Trauma (FAST) in 313 pediatric patients. *Journal of Clinical Ultrasound* 2004;32:53-61.
- [75] Thourani VH, Pettitt BJ, Schmidt JA, et al. Validation of surgeon-performed emergency abdominal ultrasonography in pediatric trauma patients. *J Pediatr Surg* 1998;33(2):322-8.
- [76] Ong AW, McKenney MG, McKenney KA, et al. Predicting the need for laparotomy in pediatric trauma patients on the basis of the ultrasound score. *J Trauma* 2003;54:503-8.
- [77] Wiencek RG, Wilson RF, Steiger Z. Acute injuries of the diaphragm. *J Thorac Cardiovasc Surg* 1986;92:989-93.
- [78] Mihos P, Potaris K, Gakidis J, et al. Traumatic rupture of the diaphragm: experience with 65 patients. *Injury* 2003;34:169-72.
- [79] Bass DH. Investigation and management of blunt renal injuries in children. *J Pediatr Surg* 1991;26:196-200.
- [80] Stein JP. Blunt renal trauma in the pediatric population: indications for radiographic evaluation. *Urology* 1994;44:406.
- [81] Bracken MB, Shepard MJ, Holford TR. Administration of methylprednisolone for 24 or 48 hours or tilidazid mesylate for 48 hours in the treatment of acute spinal cord injury. *JAMA* 1997;277(20):1597-604.